

Mandibular incisor extraction in orthodontics: A systematic review

Thirunavukkarasu Vignesh, K. P. Senthil Kumar, Senthil Kumar Tamizharasi

Department of Orthodontics and Dentofacial Orthopedics, KSR Institute of Dental Science and Research, Thokkavadi, Thiruchengode, Tamil Nadu, India

ABSTRACT

Objectives: Our objective was to evaluate the use of mandibular incisor extraction in relieving the lower anterior crowding and its advantages and disadvantages. **Materials and Methods:** A systematic review of the literature by using several electronic databases (PubMed, Medline, Cochrane library, Medline in progress, Web of science) was performed with the help of a senior health sciences librarian. The electronic search was followed up with hand searches. After applying our inclusion and exclusion criteria, the search yielded 30 articles that were then scored, based on their methodological validity. **Results:** Mandibular single incisor extraction proved to be an effective way of relieving the lower anterior crowding with good long-term stability. However, a proper case selection, lower inter-canine width, tooth size arch length discrepancy are some of the factors that influence the achievement of stable results. **Conclusion:** Mandibular incisor extraction, as discussed in this article is a good choice when all the conditions with regard to its indications are satisfied by a patient. Incisor extraction is a better choice to opt for, as the mechanics becomes simpler and good results are achievable.

Key words: Crowding, mandibular incisor extraction, tooth size arch length discrepancy


INTRODUCTION

The concept of extraction for the purpose of orthodontic treatment is not a new philosophy. Compromised orthodontic treatment can bring out perfection in treatment, provided the result is functionally and esthetically in harmony for each respective case.^[1] According to Hopkins,^[2] crowding of mandibular incisors occurs frequently with normal growth.

Address for correspondence:

Dr. Thirunavukkarasu Vignesh, Department of Orthodontics and Dentofacial Orthopedics, KSR Institute of Dental Science and Research, Thokkavadi, Thiruchengode - 637 215, Namakkal, Tamil Nadu, India.

E-mail: vigneshortho@gmail.com

Access this article online	
Quick Response Code:	Website: www.jiadsr.org
	DOI: 10.4103/2229-3019.135408

Neff^[3] found that the maxillary anterior teeth are 18-36% larger than the mandibular anterior teeth. He indicated that compensation should be made for segments that are not in harmony. The concept of removing the lower incisor for the purpose of relieving the crowding was first introduced by Hahn.^[4] Though the lower incisor extraction is not a standard approach to symmetrically treating most malocclusions, in certain clinical situations, the therapeutic aids must be adjusted to individual patient needs, even when the achieved final occlusion is not ideal.^[4] According to Kokich and Shapiro (1984), the deliberate extraction of lower incisor in certain cases allows the Orthodontist to improve the occlusion and dental esthetics with a minimum orthodontic action.^[4] However, apart from the advantages, there are certain disadvantages of lower incisor extraction as well, which is discussed elaborately in this article.

MATERIALS AND METHODS

Our search strategy for identification of studies followed the methodology outlined by the guidelines of the PRISMA (Preferred Reporting Items for Systematic reviews and Meta Analyses). The search strategies included the internationally

published research. Review articles, published bibliographies, case reports, relevant citations in articles, in English language were included.

Initial searches were carried out on PubMed, Medline, Cochrane library, Medline in progress and Web of Science. After the electronic literature search, a hand search to identify the recent publications was undertaken. The following relevant journals were searched once: *The American Journal of Orthodontics and Dentofacial Orthopedics*, the *Journal of Orthodontics* (formerly, *British Journal of Orthodontics*), the *Angle Orthodontist*, the *European Journal of Orthodontics*, and the *Journal of Clinical Orthodontics*. The search was expanded by secondarily searching the references of the selected stage 1 articles [Figure 1].

Studies that included the comparison groups were considered. Thus, randomized controlled trials, clinical trials, and prospective observational studies with concurrent or historic comparison groups were included in the review. To be of clinical benefit, the outcome of the mandibular incisor extraction must be stable over long term. Therefore, this review was restricted to clinical studies of patients who had completed a full course of fixed orthodontic treatment. No reports were excluded on the basis of population or study setting.

From the titles and abstracts derived from the searches, articles were included on the basis of human clinical studies involving mandibular incisor extraction and fixed orthodontic treatment. In stage 1, all articles were reviewed by one reviewer (first author) to determine whether each article met the predetermined inclusion and exclusion criteria.

In stage 2, all the selected articles were examined by the second reviewer (second author) to determine whether the eligibility criteria were met. For all included studies, a note was made of any flaws in the study design.

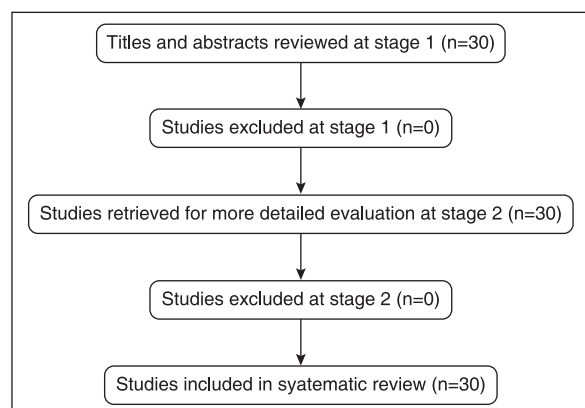


Figure 1. Flow diagram of the studies identified

RESULTS

All the studies have been included as all of them were relevant to this present study. The one common feature between all the articles cited is that none of the authors have strictly contraindicated the lower incisor extraction. All the authors have recommended the use of a diagnostic setup to assess the outcome of the treatment before doing the mandibular incisor extraction. All the case reports available were with a minimum of one year post-retention follow-up. This makes the study more reliable than the immediate de-bond reports.

Ideal indications and case selection for mandibular incisor extraction

1. Class I molar relationship indicating that the final buccal interdigitation will be acceptable.^[5] However, a full cusp Class II molar relationship with lower anterior crowding can also be an ideal case.
2. Ideal or normal upper arch, which could be just corrected by inter-proximal enamel reduction alone cannot be considered for lower incisor extraction.
3. Soft-tissue profile should be normal as there will be minimal change in the upper arch, which will be an ideal case.^[5]
4. In a full cusp Class II molar case with lower anterior crowding, upper premolar extraction with lower one incisor extraction can also yield a functionally and esthetically stable result.
5. Minimal growth potential.^[5] In growing patients, non-extraction therapy should be considered.
6. Missing lateral incisors or peg laterals, which can solve the inevitable tooth size discrepancy without any stripping or re-contouring.^[5]
7. Class I cases with anterior dental cross-bite, which is due to lower anterior crowding or lower anterior protrusion can be considered.^[1]
8. Extreme crowding or protrusion, particularly when accompanied by gingival recession and bone loss can also be an indication for lower incisor extraction.^[6]
9. Maxillary dentition with a narrow lateral incisor (measurable mandibular Bolton excess) may represent good indication for extraction of one mandibular incisor.^[5,7-9]
10. Cases with borderline Class III or a Class III tendency are also indicated for lower incisor extraction because some collapse of lower arch may be acceptable or even desirable in such instances.^[1,4,9-11]
11. Tooth Size Arch Length Discrepancy (TSALD) in the mandibular arch is an indication for extraction of single mandibular incisor, when there is no adequate space in the arch to accommodate a full complement of teeth^[12] (TSALD greater than 5 mm in lower anterior region).^[13]
12. Presence of deep curve of Spee, proclined lower anteriors where uprighting can be easily done with a single lower incisor extraction.^[12]
13. Extraction of lower incisor is indicated where there is ectopic eruption and there is presence of normal

intercanine width. Altering the intercanine width may pose stability issues and so also there is a natural tendency towards decrease in intercanine width as age advances.^[12]

14. It is also indicated in cases, where in the final finishing, when six maxillary anterior teeth are occluding with five mandibular anterior teeth, an ideal Class I canine relation is obtained and the distoincisor inclines of the maxillary canine occlude with the mesioincisor inclines of mandibular first premolars.^[12]

Advantages of mandibular incisor extraction

1. It may reduce the treatment time, if the crowding is limited to anterior region.^[13]
2. In case of lower single incisor extraction there is only a minimal alteration in intercanine width, which does not pose a threat to the long-term stability.^[14]
3. Incisor extraction therapy does not demand much retraction of the anterior teeth. So the antero-posterior position of the incisors is not changed much, allowing the profile to be maintained.^[1]

Disadvantages of mandibular incisor extraction

1. Overjet increases if there was no Bolton discrepancy before the start of treatment.^[13]
2. A Class III occlusal relationship will be the result, if the overjet is normal after the removal of lower incisor.^[13]
3. A midline discrepancy is inevitable and there are chances for extraction space to reopen in the long term.^[12,14]
4. As the morphology of the lower incisor are in such a way that the cervical portion of the crown is narrower mesiodistally and wider incisally, extracting a single incisor may lead to sacrifice of inter-dental papilla leading to 'black triangle' formation.^[6,15]

Decision making for which incisor to extract

The critical decision of which lower incisor to extract on several considerations, including periodontal condition, the presence of gingival recession and the location of any restoration, including endodontic treatment.^[16]

Additionally, a mesiodistal width of each incisor should be measured and the anticipated amount of tooth movement determined with the Bolton analysis keeping in mind that in mandible, the central incisors are smaller mesiodistally than lateral incisor.^[1,16]

According to Flavio Uribe and Ravindra Nanda,^[16] extraction of a lateral incisor is generally preferred because it is less visible from the front.^[1] But the incisor that is farthest outside the natural arch and the closest to the crowding is usually the best tooth for extraction.

DISCUSSION

The concept of extraction of teeth to alleviate the crowding is not a new practice. Extraction of mandibular incisor for

the purpose of relieving the lower anterior crowding is also not a new concept. In 1904,^[17] a case has been described, in which two lower incisors were extracted at different times to relieve the mandibular crowding.

Non-extraction therapy in crowded cases is usually thought to lead to post-retention relapse.^[14] There was a study^[18] involving the evaluation of post-treatment crowding of mandibular incisors, which shows that there was no correlation between a change in the post-retention intercanine width and post-retention mandibular anterior crowding. It has been observed that there is less post-retention incisor irregularity in the non-extraction patient than in extraction patient.

In contrast, a thesis study done to evaluate the long-term stability of mandibular arch^[19] states that premolar extraction cases had less tendency to become crowded than patients treated as non-extraction. No significant correlation was found between pre-treatment and post-retention incisor alignment and no significant correlation between stability (or relapse) and changes in mandibular incisor position or angulation.^[14]

A study of non-extraction orthodontic therapy to assess post treatment dental stability,^[20] confirms the long-term stability of a crowded non-extraction sample. In this study, the arches were enlarged slightly during treatment and it responded favorably during the post-retention stage. Inter-molar width increased during treatment and showed minimal decrease in post-retention. Cephalometric findings did not show any significant change that contributed to post-retention relapse.

When evaluating an untreated sample with the normal occlusion,^[21] it has been found that arch length and width decreased throughout the second decade of life. Many other authors,^[22] also found the same pattern of arch constriction in patients with generalized spacing.

It is generally agreed that patient treated with the extraction of four premolars tend to experience a decrease in mandibular intercanine width and an increase in incisor irregularity post-retention, regardless of whether arch width has been expanded or constricted.^[23-27]

In an effort to find predictors for the relapse of mandibular anterior crowding, a study^[25] was done to assess 65 patients, all at least 10-years post-retention. All patients have been treated in permanent dentition with first premolar extraction. The long-term response to mandibular anterior alignment was unpredictable. No variables such as degree of initial crowding, age, gender, angle's classification etc. were useful in establishing the prognosis. Seventy percent of patients had unsatisfactory mandibular anterior alignment in the post-retention stage. Patients who

were slightly crowded before treatment usually become moderately crowded.^[14]

In another study,^[26] which was done to investigate whether a similar trend occurred from 10 to 20 years of post-retention, it has been reported that the crowding continued to increase during the later phase, but to a lesser degree than during first 10 years of post-retention. Only 10% of the patients were judged to have clinically acceptable mandibular alignment at the last stage of diagnostic records.

A study done to evaluate the post-retention stability of mandibular incisors^[14] has reported that in patients with severely crowded mandibular arches, the removal of one or more mandibular incisor is the only logical alternative, which may allow for increased stability of the mandibular anteriors without continued retention.

A study done in the University of Washington, Department of Orthodontics, demonstrated that out of several cases treated in 1940s with a two incisor extraction plan and no retention, two cases alone with a follow-up of four years of post-treatment illustrate acceptable stability.^[14]

A study involving post-treatment appraisal of orthodontic results^[28] done by reviewing 20 years of post-retention records of a patient, who was congenitally missing two mandibular incisors showed good long-term stability. After informally reviewing 10 year post-retention records of patients who had two mandibular incisors removed,^[29] it has been observed that the arches in these patients appeared less crowded post-retention than those of similar patients, who had been treated with premolar extraction.

A review^[30] of Edward Hartley Angle's philosophy of extraction in Orthodontics, showed that Angle regarded the extraction of an incisor even when the tooth was sound. Furthermore, Angle warned that extracting one incisor, as advocated by some, would lead to less acceptable harmony between the occlusal plane of the remaining teeth, in addition to an abnormal incisor overbite.^[14]

A case report^[7] of four patients who were successfully treated with extraction of single mandibular incisor showed that with the careful case selection, single incisor extraction may allow the practitioner to use simple treatment mechanics and achieve good results.

CONCLUSION

Mandibular incisor extraction, as discussed in this article is a good choice when all the conditions with regard to its indications are satisfied by a patient. Judicious extraction without proper planning should be avoided, as it may lead to excess overjet, overbite and occlusion, which are not functionally stable. A proper diagnostic setup is always recommended before

doing mandibular incisor extraction, so that a proper idea regarding the post-treatment occlusion can be obtained. It is better to avoid incisor extraction if the diagnostic setup does not yield a satisfying post-treatment occlusion. Otherwise, incisor extraction is a better choice to opt for, as the mechanics becomes simpler and good results are achievable. Midline compromise will not pose an esthetic problem as the lower midline is not visible in a normal social smile.

REFERENCES

1. Bahreman AA. Lower incisor extraction in orthodontic treatment. *Am J Orthod* 1977;72:560-7.
2. Hopkins C. Inadequacy of mandibular anchorage 5 years later. *Am J Orthod* 1960;46:443.
3. Neff CW. The size relationship between the maxillary and mandibular anterior segments of the dental arch. *Angle Orthod* 1957;22:146.
4. Canut JA. Mandibular incisor extraction: Indications and long term evaluation. *Eur J Orthod* 1996;18:485-9.
5. Owen AH. Single lower incisor extractions. *J Clin Orthod* 1993;27:153-60.
6. Faerovig E, Zachrisson BU. Effects of mandibular incisor extraction on anterior occlusion in adults with Class III malocclusion and reduced overbite. *Am J Orthod Dentofacial Orthop* 1999;115:113-24.
7. Kokich VG, Shapiro PA. Lower incisor extraction in orthodontic treatment: Four clinical reports. *Angle Orthod* 1984;54:139-53.
8. Tuverson DL. Anterior interocclusal relations. Part II. *Am J Orthod* 1980;78:371-93.
9. Richardson ME. Extraction of lower incisors in Orthodontic treatment planning. *Dent Pract* 1963;14:151-56.
10. Hahn G. Problems in treatment of malocclusions. *Angle Orthod* 1942;12:61-82.
11. Doppel DM. Case report FG. Orthodontic treatment to correct major dental asymmetries. *Angle Orthod* 1991;61:231-4.
12. Valinoti JR. Mandibular incisor extraction therapy. *Am J Orthod Dentofacial Orthop* 1994;105:107-16.
13. Prakash A, Tandur AP, Dunganwal N, Bhargava R. Mandibular incisor extraction case report. *Virtual J Orthod*, 2011 September 22.
14. Riedel RA, Little RM, Bui TD. Mandibular incisor extraction-postretention evaluation of stability and relapse. *Angle Orthod* 1992;62:103-16.
15. Sheridan JJ, Hastings J. Air-rotor stripping and lower incisor extraction treatment. *J Clin Orthod* 1992;26:18-22.
16. Uribe F, Nanda R. Considerations in mandibular incisor extraction cases. *J Clin Orthod* 2009;43:45-51.
17. Jackson VH. Orthodontia and orthopaedia of the face. Philadelphia: J. B. Lippincott Co.; 1904.
18. Gallerano RL. Mandibular anterior crowding – A post retention study. University of Washington Master's thesis; 1978.
19. Witzel DA. Long term stability of the mandibular arch following differential management of arch length deficiencies. University of Washington Master's thesis; 1978.
20. Glenn G, Sinclair PM, Alexander RG. Nonextraction orthodontic therapy: Post treatment dental and skeletal stability. *Am J Orthod Dentofacial Orthop* 1987;92:321-8.
21. Sinclair PM, Little RM. Maturation of untreated normal occlusions. *Am J Orthod* 1983;83:114-23.
22. Little RM, Riedel RA. Postretention evaluation of stability and relapse-mandibular arches with generalized spacing. *Am J Orthod Dentofacial Orthop* 1989;95:37-41.
23. Shapiro PA. Mandibular dental arch form and dimensions. Treatment and postretention changes. *Am J Orthod* 1974;66:58-70.
24. Gardner SD, Chaconas SJ. Posttreatment and postretention changes following orthodontic therapy. *Angle Orthod* 1976;46:151-61.
25. Little RM, Wallen TR, Riedel RA. Stability and relapse of mandibular anterior alignment-first premolar extraction cases

- treated by traditional edgewise orthodontics. *Am J Orthod* 1981;80:349-65.
26. Little RM, Riedel RA, Artun J. An evaluation of changes in mandibular anterior alignment from 10 to 20 years postretention. *Am J Orthod Dentofacial Orthop* 1988;93:423-8.
27. Uhde MD, Sadowsky C, Begole EA. Long-term stability of dental relationships after orthodontic treatment. *Angle Orthod* 1983;53:240-52.
28. Schwarz. Post treatment appraisal of orthodontic results. *Trans Eur Orthod Soc* 1961;1:87-9.
29. Riedel RA, Brandt S. Dr. Richard A. Riedel on Retention and relapse. *J Clin Orthod* 1976;10:454-72.
30. Salzmann. Editorial: EH Angle on extraction in orthodontics. *Am J Orthod* 1963;49:464-6.

How to cite this article: Vignesh T, Senthil Kumar KP, Tamizharasi SK. Mandibular incisor extraction in orthodontics: A systematic review. *J Indian Acad Dent Spec Res* 2014;1:1-5.

Source of Support: Nil, **Conflict of Interest:** None declared