Case Report

# Residual radicular cyst in primary molar extraction socket: An unusual clinical entity

*Savitha Satyaprasad, S.H. Krisnamoorthy, Ambili Ayilliath, Somesh Kishore*

Department of Pedodontics, KVG Dental College and Hospital, Sullia, Karnataka, India

## ABSTRACT

Radicular cyst is a most common type of odontogenic cyst that develops mostly as sequel of untreated dental caries. It is classified as inflammatory type originated mostly from cell rests of Malassez. Radicular cyst arising from deciduous teeth is rare, accounting for just 0.3% to 5% of the total number. Residual kind of radicular cyst in deciduous teeth are still very sparse in literature. Most of the residual cysts are asymptomatic and are found only on routine radiographic examination. We are presenting an interesting and rare case of symptomatic residual radicular cyst of left primary first molar extraction socket with secondary infection in a 5-year-old child. Our aim is to emphasize on investigations, recognition, and treatment of such inflammatory residual radicular lesions associated with deciduous teeth, which has been an unreported clinical entity.

**Key words**: Deciduous teeth, radicular cyst, residual cyst,

## INTRODUCTION

Radicular cysts are the most common inflammatory jaw cysts and develop as a sequel of untreated dental caries with pulp necrosis and periapical infection.[1] Although dental caries is very common in children; however, radicular cysts affecting deciduous dentition appear to be rare with the incidence being as low as 0.5% to 3.3% of the total number of radicular cysts in primary and permanent teeth.[2] Residual radicular cysts are those inflammatory periodontal cysts that are periapical in position and persist after removal of the associated tooth. They represent approximately 10% of all odontogenic cysts,[3,4] but are not included within the WHO classification.[5] Oehlers[6] made a radiographic study of 168 presumed residual cysts, left *in situ* for periods of up to 7 years and concluded that most lesions resolved, while a small percentage remained static and in none of the cases increased in size, due to repair following removal of the irritant process. Killey and Kay[4] described incidence figures for residual cysts during an 11-year period; residual cysts were more common in the maxilla (61%). Cases of symptomatic residual radicular cyst of primary dentition are very sparsely found in literature. Hence, we are presenting a case of residual radicular cyst in left side of primary mandibular molar socket with secondary infection.

## CASE REPORT

A patient aged 5 year reports to Department of Pedodontics and Preventive Dentistry with a chief complain of pain,

**Address for correspondence**:
Dr. Somesh Kishore,
Department of Pedodontics, KVG Dental College and Hospital,
Sullia, Karnataka, India.
E-mail: someshkishore@400gmail.com

| Access this article online | |
|---|---|
| Quick Response Code: | **Website:** www.jiadsr.org |
| | **DOI:** 10.4103/2229-3019.192469 |



How to cite this article: Satyaprasad S, Krisnamoorthy SH, Ayilliath A, Kishore S. Residual radicular cyst in primary molar extraction socket: An unusual clinical entity. J Indian Acad Dent Spec Res 2016;3:25-8.

swelling, and pus discharge in lower left back tooth region since 2 days. Patient provided history of tooth removal 1 month back. History of pus discharge in the same tooth region, which increases while having food was given. Patient had taken medication for pain. No contributory medical history. On clinical examination, a diffuse swelling seen in lower body of mandible region on left side which is size 1 × 0.75 cm and tender on palpation . Facial asymmetry is seen. Submandibular lymph node on left side is tender and palpable and slightly enlarged [Figure 1]. On intraoral examination, adjacent to left mandibular molar extraction socket, obliteration of buccal sulcus with slight erythema was observed [Figure 2]. On palpation, hard bony expansile vestibular swelling extending from 73 to 75 was found.

Periapical radiograph showed radiolucent lesion with ill-defined irregular border with respect to extraction socket [Figure 3]. Panaromic radiograph revealed hazy radiolucent lesion of 1 × 1.5 cm. Ill-defined irregular border in the tooth space of 74. Occlusal radiograph confirmed the expansion of buccal cortical plate. Expansion of buccal cortex with thinning seen, which was extending from distal of 73 to beyond distal aspect of 75 of size 3.5 × 1 cm with hazy internal structure was observed [Figure 4]. Computed tomography revealed a well-defined lytic lesions within the left mandible in the primary molar region with cortical plate expansion measuring 13 × 19 mm suggestive of odontogenic cyst [Figure 6]. The contents of the lesion was aspirated and on histopathological examination; it was found that the lesion contains predominantly acute inflammatory cells admixed with few lymphocytes and plasma cells in pool of RBC ( Red blood corpuscles), CT (Computed Toography), which was suggestive of infection [Figure 7]. Taking into consideration of clinical, radiographic, and aspiration cytology report, a provisional diagnosis of infected residual cyst was made and surgical curettage was planned. Under local anesthesia incision was made from 73 to 75, flap was raised and cystic site was exposed [Figure 8]. Careful curettage was done with intermittent irrigation. Surgical exploration confirmed that it was not communicating with permanent bud. Flap was sutured back [Figure 9]. Curetted tissue was sent for histopathological examination [Figures 10 and 11]. Excisional Biopsy report showed proliferating nonkeratinized stratified squamous epithelium. Supporting connective tissue wall was fibrocellular consisting of delicate collagen fibers moderately infiltrated with both acute and chronic inflammatory cells suggestive of radicular cyst [Figure 5].

**Figure 1: Frontal profile of patient.**

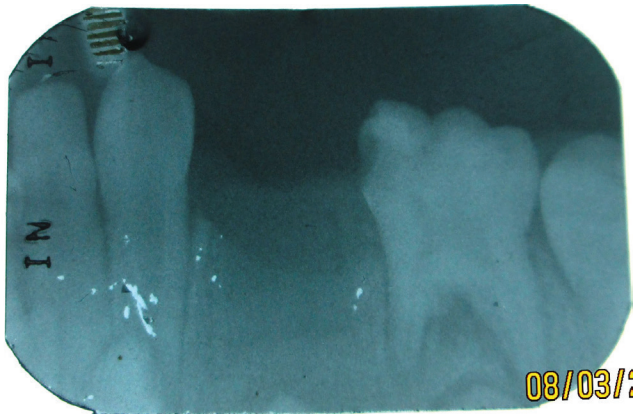

**Figure 3: Intraoral periapical radiograph with radiolucent lesion of 1 × 1 with ill-defined irregular border wrt extraction socket.**

**Figure 2: Intraoral picture showing obliteration of buccal sulcus.**

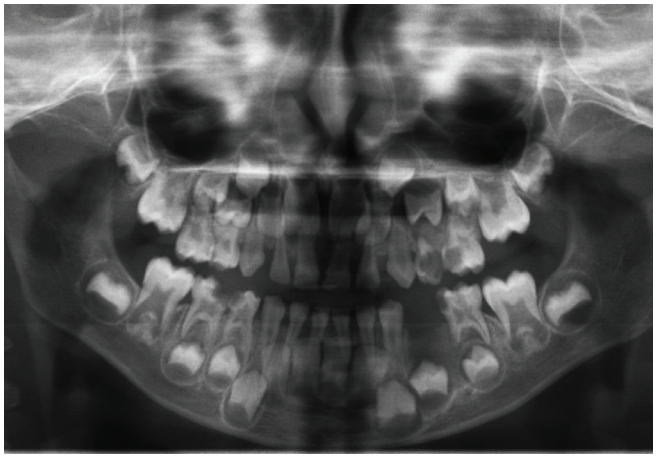

**Figure 4: Panoramic radiograph showing hazy radiolucent lesion of 1 × 1.5 ill-defined irregular border wrt extraction socket.**

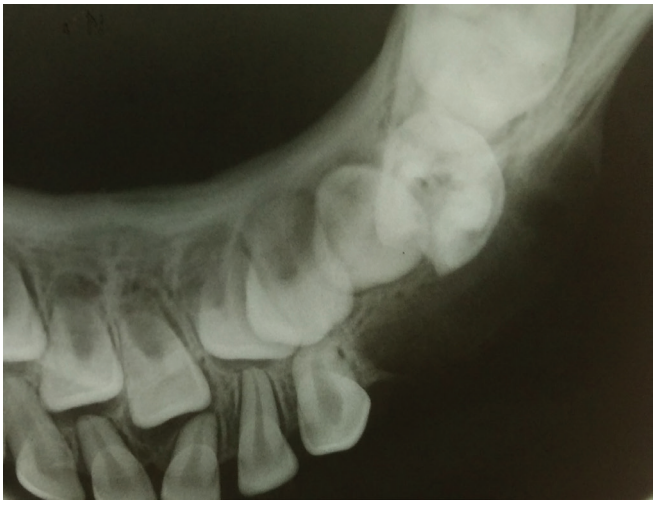

**Figure 5: Occlusal radiograph showing bony expansion with thinning extending from 73 to 75.**

**Figure 8: Intra Operative View**

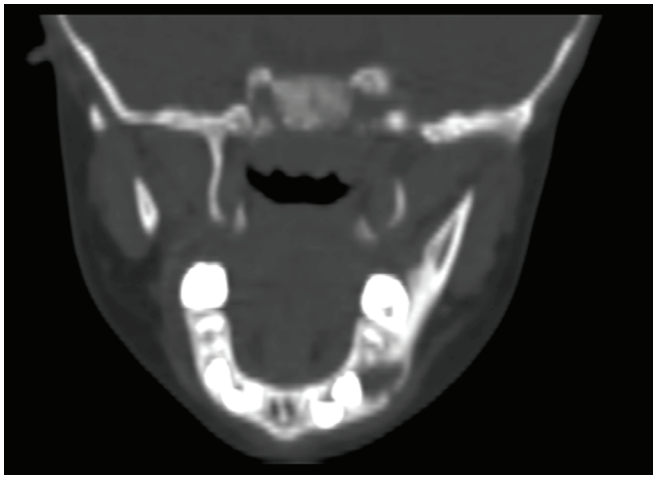

**Figure 6: CT scan showing well-defined lytic lesion with cortical plate expansion in left mandibular primary region.**

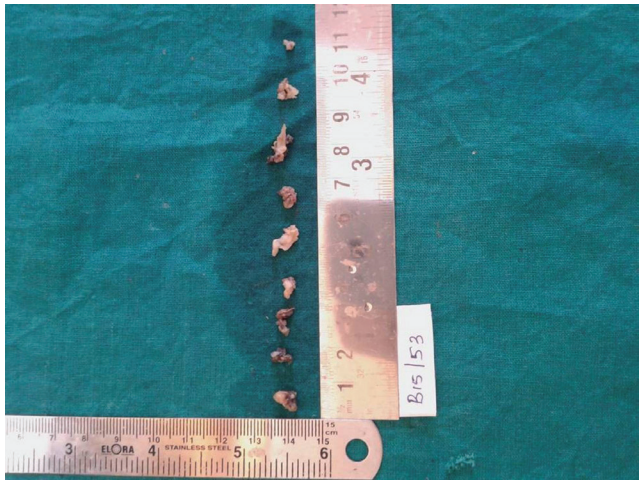

**Figure 9: Intraoperative picture of patient after surgical curettage.**

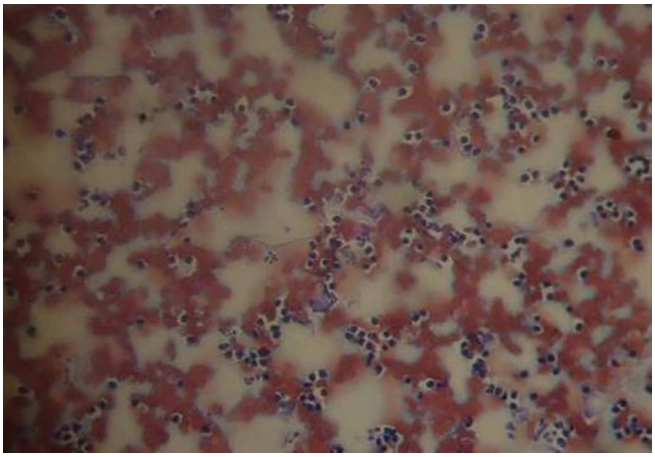

**Figure 7: Aspiration cytology showing predominantly inflammatory cells**

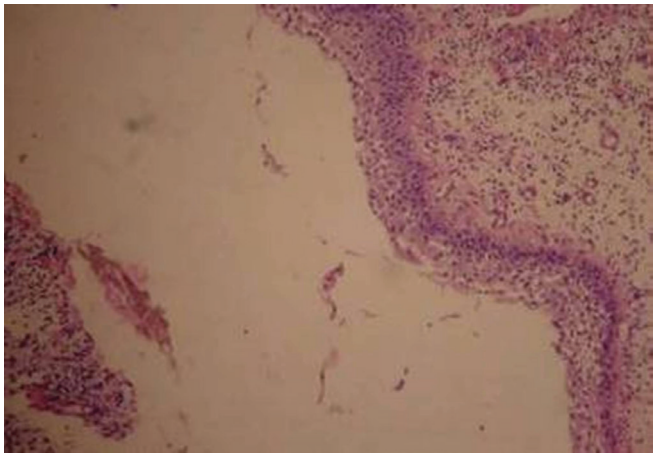

**Figure 10: Sample sent for biopsy.**


**Figure 11: Histopathological picture of biopsy material.**

After 7 days, patient was recalled for suture removal. After 15 days, the swelling had completely reduced, obliteration, and erythema disappeared.

## DISCUSSION

Radicular cysts can occur in the periapical region of any teeth, at any age, but seldom seen associated with the primary dentition.[7] Lustmann and Shear[8] in an extensive review from 1898 to 1985 found 51 cases, and Nagata *et al.*[9] in their review reported 112 cases through 2004. A review by Shear and Speight in 2007 showed that out of the 948 radicular cysts only 16 (1.7%) were seen in Johannesburg occurred in pediatric patients (0–9 years).The reason for this may be the short period for which the deciduous teeth remain in oral cavity, easy drainage, and very low number of teeth are brought for histopathological examination after extraction.[9]

Residual radicular cyst till now has been reported by Rohan *et al.*[10] Most of the residual cysts are asymptomatic and eventually heal with time,[6] particularly in primary dentition because the source of infection has been removed. In our case, we did extensive investigations to rule out other possible diagnosis. Panoramic radiograph to rule out dentigerous cyst, which is most common at this age because the radiolucency was not involving the tooth bud of 34. Occlusal radiograph showed expansion of cortex with thinning giving the possibility of either cyst or neoplastic growth. CT scan report showed it to be a lytic lesion suggestive of odontogenic cyst in the primary mandibular area. Localization of retained residual cyst by CT scan had been reported by Jmadade *et al*, alike our case. Aspiration cytology was done to rules out any vascular lesion and it helps in differential diagnosis, according to Whitten. Aspiration was positive, so any neoplastic proliferation was ruled out and histopathological report indicated infection. So provisional diagnosis of infected residual cyst was made and surgical curettage was performed.

In our case since the cystic lesion was symptomatic with secondary infection, so the patient did report the same. But in most cases, this kind of lesion remains unreported and undiagnosed. However, the most important thing is to avoid its adverse effects on permanent tooth bud, which include delayed eruption, malpostion, enamel defect, and may even lead to nonvitality of permanent tooth.

## CONCLUSION

Considering the adverse effects of cyst on permanent dentition, an early diagnosis and timely appropriate treatment should be instituted. This article tries to give pedodontist a new clinical scenario, which shows the existence of residual cyst that may have far-reaching consequences on dentition.

### Acknowledgment
Nil

### Financial support and sponsorship
Nil.

### Conflicts of interest
There are no conflicts of interest.

## REFERENCES

1. Jones AV, Craig GT, Franklin CD. Range and demographics of odontogenic cysts diagnosed in a UK population over a 30-year period. J Oral Pathol Med 2006;35:500-7.
2. Shear M. Cysts of the Oral Regions: Radicular and Residual Cysts. 1992;3rd edBostonWright136-62.
3. Main DMG. Epithelial jaw cysts: A clinicopathological reappraisal. Br J Oral Maxillofac Surg 1970;8:114.
4. Killey HC, Kay LW, Seward GR. Benign Cystic Lesions of the Jaws, Their Diagnosis and Treatment. 1977;3rd edEdinburghChurchill Livingstone169.
5. Pindborg JJ, Kramer IRH, Torloni H. Histological Typing of odontogenic tumours, Jaw cysts and Allied Lesions. 1971;Geneva WHO
6. Oehlers FAC. Periapical lesions and residual dental cysts. Br J Oral Maxillofac Surg 1970;8:103.
7. Grewal HK, Batra R. Nonsyndromic bilateral dentigerous cysts: A case report. Int J Dental Clin 2010;2:49-51.
8. Lustmann J, Shear M. Radicular cysts arising from deciduous teeth. Review of the literature and report of 23 cases. Int J Oral Surg 1985;14:153-61.
9. Nagata T, Nomura J, Matsumura Y, Yanase S, Fujii T, Oka T. Radicular cyst in a deciduous tooth: A case report and literature review. J Dent Child (Chic) 2008;75:80-4.
10. Bhatt R, Atrey A, Sharma S, Reddy SS, Chen T. Residual periradicular cyst: A call for pediatric dentist. J Res Adv Dent 2013;2:55-8.
11. Jamdade A, Nair GK, Kapoor M, Sharma N, Kundendu A. Localisation of peripheral residual cyst: diagnostic role of CT scan. Case Reports in dentistry 2012;2012.