Original Article

The effect of biostimulation with 980-nm diode laser on postoperative pain and tissue response after surgical periodontal therapy: A pilot study

Monica Ravi, H. Esther Nalini, Arun Kumar Prasad, R. Renuka Devi

Department of Periodontology, K. S. R. Institute of Dental Science and Research, Tiruchengode, Tamil Nadu, India

ABSTRACT

Aim: The aim of this study was to compare the postoperative pain and tissue response (TR) after biostimulation with a diode laser (980 nm) (DL) as an adjunct to Kirkland flap surgery (KF) to that of KF alone. **Materials and Methods:** A total of 9 patients with generalized severe chronic periodontitis indicated for periodontal surgical management were included in the study. Control sites were randomly selected to receive a KF and the contralateral test sites received biostimulation with DL after KF. Randomization was performed using a coin flip. Pain scale assessment and pain medication consumption were evaluated 3 days after surgery and TR with frail elder's gingival inflammation index was evaluated 1 week after surgery. **Results:** Pain response on day 2 is significantly lesser in the test group than the control group ($P = 0.013$). TR did not show a statistically significant difference between the two groups ($P = 0.35$). Mean number of tablet consumption after surgery is greater when compared with the laser intervention. **Conclusion:** The use of a 980-nm DL had a significant effect on the immediate postoperative pain and thus reducing the need for analgesic consumption.

Key words: Biostimulation, flap surgery, low-level laser therapy, postoperative pain

INTRODUCTION

The term "LASER" is an acronym of "Light Amplification by Stimulated Emission of Radiation." The discovery of lasers was based on Einstein's stimulated emission of radiation theory. The first laser apparatus was built by Theodore H. Maiman in 1960. Since then, researchers have investigated the effectiveness of low- and high-intensity lasers in the field of dentistry, especially in periodontology.[1]

Address for correspondence:
Dr. Monica Ravi,
654, Valayakara Street, Erode - 638 001, Tamil Nadu, India.
E-Mail: monicaravi@me.com

Access this article online	
Quick Response Code:	**Website:** www.jiadsr.org
	DOI: 10.4103/jiadsr.jiadsr_9_17

Since Mester first showed in 1967, that there was enhanced wound healing in mice stimulated with a ruby laser, treatment with low-intensity lasers to improve wound healing has been applied.[2] Two theories are commonly accepted to explain these effects of laser irradiation on tissues. The first theory is based on the principle that the light of a specific wavelength activates the mitochondrial respiratory chain of the cell[3] and the second theory postulates that the light of a specific wavelength opens the calcium channels on the cell membrane thus increasing the cellular metabolism with a higher production of adenosine triphosphate.[4]

How to cite this article: Ravi M, Nalini HE, Prasad AK, Devi RR. The effect of biostimulation with 980-nm diode laser on postoperative pain and tissue response after surgical periodontal therapy: A pilot study. J Indian Acad Dent Spec Res 2016;3:47-51.

Another mechanism by which low-intensity lasers acts on wound healing is by enhancement of the blood supply. At the time of surgery, biostimulation with laser brings about an increase in blood flow that leads to the recruitment of proinflammatory and anti-inflammatory cytokines and growth factors to the wound site. During the initial phase of inflammation, biostimulation can stimulate degranulation of mast cells, unleashing the inflammatory response. Thereafter, it enhances the proliferation of fibroblasts, osteoblasts, and epithelial cells. It also increases protein synthesis and the release of growth factors by these cells. All these events together, lead to faster clinical wound healing.[1]

Various studies have investigated the role of lasers to improve wound healing, with inconsistent results. Both animal studies and human studies show beneficial[2,5,6] and negative effects.[7-10] The biostimulation with lasers depends on various parameters such as wavelength of the laser, laser output power, energy density, and irradiation time. Therefore, it is critical to use the correct combination of parameters to achieve the desired effects.

Periodontal wound healing and pain reduction have been found to be enhanced by low-level lasers. Photoreceptors within subcellular components absorb the visible red and near-infrared wavelengths emitted by low-level lasers that target the electron transport/respiratory chain within the membranes of mitochondria. Absorption of laser energy increases adenosine triphosphate formation, which, in turn, stimulates cell function. This increase in cell function may favor improved wound healing. *In vitro* studies have shown that low-level laser therapy (LLLT) increases the synthesis of collagen, and procollagen, and also to stimulate and increase the proliferation rate of fibroblasts.[11]

Periodontal disease is not a painful disease. Periodontal surgery that follows the basic principlesshould produce only minor pain and discomfort.[12] However, the treatment of periodontal diseases is experienced as painful by many patients.[11] Although various studies have evaluated the effects of LLLT on healing, the effect that LLLT has on postoperative pain are still under investigation. In view of the lack of evidence for benefits of laser in reducing the discomfort of the patients, the present study evaluated whether the adjunctive use of a diode laser (DL) would improve the tissue response (TR) and would reduce postoperative pain after Kirkland flap (KF) surgery.

MATERIALS AND METHODS

Patients were recruited from the outpatient ward, Department of Periodontology, K. S. R. Institute of Dental Science and Research, Tiruchengode, Namakkal district, Tamil Nadu and were treated from July 2016 to October 2016. A total of 13 patients (7 males and 6 females) were included in this study. Study protocol was explained to the patients, and written informed consent and institutional ethical clearance were obtained.

The inclusion criteria were two contralateral quadrants, with at least 2 teeth with a probing depth ≥7 mm; clinical attachment loss ≥5 mm and a gingival index ≥1. Exclusion criteria were long-term steroidal or antibiotic therapy, systemic diseases likely to affect wound healing or pregnant and lactating women.

A total of 13 patients were enrolled and received the intended treatment. Totally 4 patients dropped out after the surgical procedures because they could not keep up the appointments for review. Written informed consent form was signed by each patient. The study informed consent form was approved by the Institutional Review Board.

This study was designed as a randomized, single-masked, split-mouth clinical trial. The patient did not know which site received biostimulation with laser. One clinician enrolled, evaluated, and treated all patients. The primary outcome with respect to the effect of laser use during periodontal surgery was the reduction of self-reported immediate postoperative pain as measured by the modified visual analog scale and daily intake of pain medication (PM).

All patients received a Phase I therapy including oral hygiene instructions, supragingival and subgingival scaling and root planing with manual and ultrasonic instruments ≥4 weeks before surgical therapy. After re-evaluation, randomization was performed by coin toss method and the control sites were treated with KF and sham laser exposure. The test sites received KF with the application of an active DL for biostimulation. The time between the two surgeries was 1 week.

Surgical procedure

Under local anesthesia, sulcular incision was given, full thickness mucoperiosteal flap was elevated, granulation tissues were removed with manual instruments, and root surfaces were scaled and planed with Gracey Curettes [Figure 1]. In the test sites, an indium – gallium – arsenide (In – Ga – Ar) DL with a wavelength 980 nm and 0.1W at continuous mode was applied in a noncontact mode [Figure 2]. All surfaces of the flap, inner and outer, exposed bone, and exposed root structures involved in the surgery were irradiated, leading to a total dosage of 4 J/cm^2/surface. In the control sites, laser application was simulated without pushing the start button. The flap was sutured with 4-0 black silk and surgeries performed on all patients were virtually identical. All procedures were completed within a 90 min time frame.

The patients were advised to abstain from their regular oral hygiene practice including brushing with their preoperative daily toothbrush and flossing and chewing in the treated area for 2 weeks. Chlorhexidine mouth rinses were prescribed.

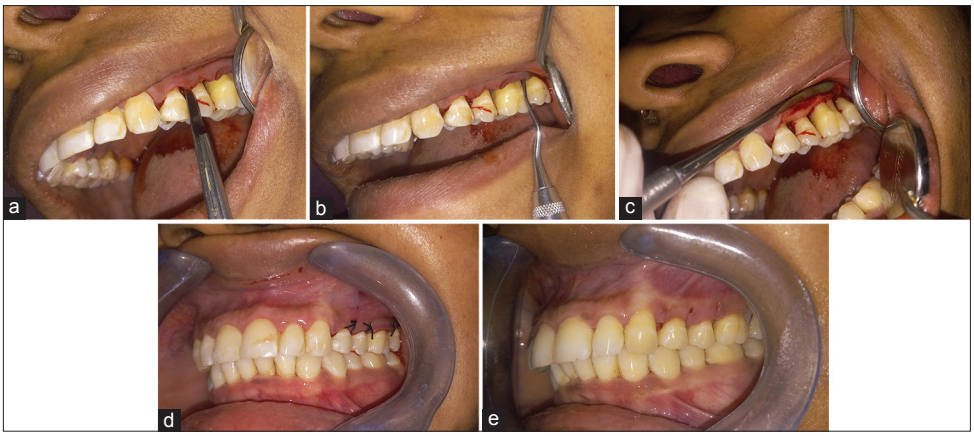

Figure 1: (a) Control sites: Sulcular incision given. (b) Control sites: Full-thickness mucoperiosteal flap elevated, scaling, root planing, and curettage done. (c) Control sites: Saline irrigated. (d) Control sites: Sutures placed. (e) Control sites: 1 week postoperative

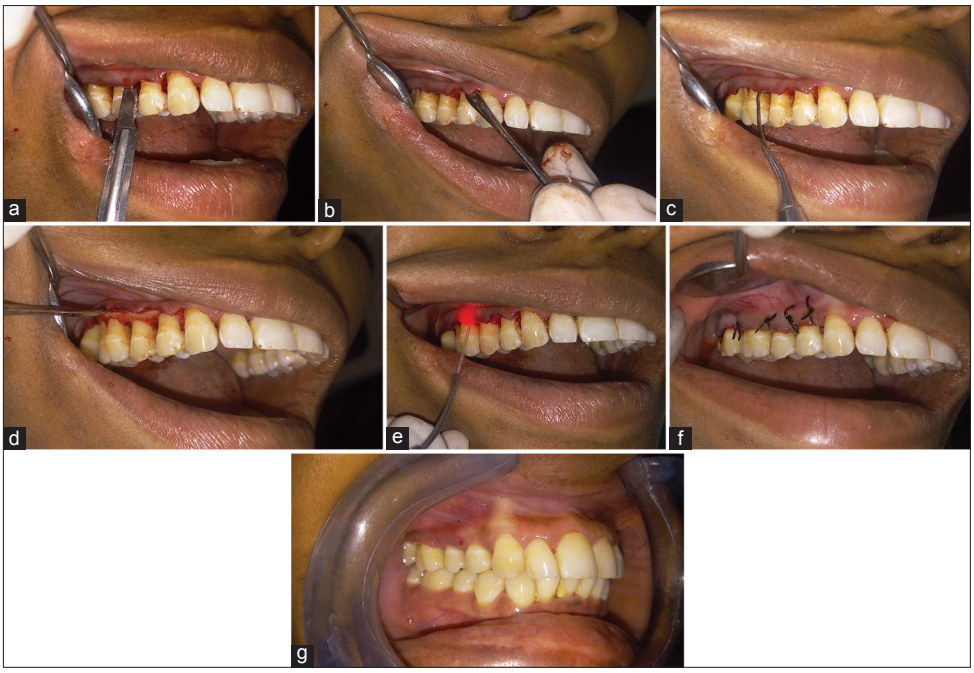

Figure 2: (a) Test sites: Sulcular incision given. (b) Test sites: Full thickness mucoperiosteal flap elevated. (c) Test sites: scaling, root planing, and curettage done. (d) Test sites: Saline irrigated. (e) Test sites: Biostimulation done with diode laser. (f) Test sites: sutures placed. (g) Test sites: 1 week postoperative

The patients resumed the oral hygiene practice and function after 2 weeks. Ibuprofen at 200 mg (up to three tablets) every 8 h was allowed as PM. The primary outcome with respect to the effect of biostimulation with laser during periodontal surgery was the reduction of self-reported immediate postoperative pain as measured daily at night for 3 days using a modified visual analog scale (graduated from 0 to 10) and daily consumption of 200 mg ibuprofen tablets. The secondary outcome was TR with regard to the levels of TR based on frail elders gingival inflammation index.[13]

The daily modified visual linear scale and the self-reported consumption of PM were returned to the examiner, 1 week later. Sutures were also removed, and TR was evaluated at the study site with Gingival Inflammation Index for Frail Elders. Study hypothesis of the primary and secondary outcomes was analyzed using paired *t*-tests and Chi-square tests. Differences associated with $P < 0.05$ were considered statistically significant.

RESULTS

Tissue response

No post-operative complications were observed in any patients. TR was evaluated 1 week after surgery. Nearly 44.4% and 55.6% of the patients showed minimum and moderate

Table 1: Tissue response before and after the respective interventions

	Tissue response after surgery, *n* (%)	Tissue response after diode, *n* (%)	*P* (<0.05)
Minimum	4 (44.4)	8 (88.9)	0.35
Moderate	5 (55.6)	1 (11.1)	
Excessive	0	0	
Total	9 (100)	9 (100)	

Table 2: Pain response before and after the respective interventions

	Pain response after surgery and diode				*P*
	Mean	*n*	SD	SEM	
Day 1					
Pain response surgery	6.43	9	1.718	0.649	0.078
Pain response diode	4.86	9	2.545	0.962	
Day 2					
Pain response surgery	4.43	9	0.787	0.297	0.013
Pain response diode	3.29	9	2.498	0.944	
Day 3					
Pain response surgery	3.71	9	1.890	0.714	0.915
Pain response diode	1.43	9	1.512	0.571	

SD = Standard deviation, SEM = Standard error of mean

Table 3: Pain medication consumption before and after the respective interventions

	Mean±SD
Number of tablets consumption after surgery	1.71±1.113
Number of tablets consumption after diode	0.71±0.756

SD = Standard deviation

inflammation after KF surgery, whereas 88.9% and 11.1% of the patients showed minimum and moderate inflammation, respectively, after KF surgery followed by biostimulation with laser [Table 1]. The insignificant *P* value (0.35) reveals there is no statistically significant difference between the two groups with regard to TR.

Postoperative pain

The mean pain response on day 1 was 6.43 ± 1.72 and 4.86 ± 2.55 ($P = 0.078$), on day 2 was 4.43 ± 0.79 and 3.29 ± 2.50 ($P = 0.013$), and on day 3 was 3.71 ± 1.89 and 1.43 ± 1.512 ($P = 0.915$) for KF surgery and KF surgery followed by biostimulation with laser, respectively [Table 2]. The significant *P* value (0.013) on day 2 implies that pain response on day 2 is significantly reduced by biostimulation with laser.

Pain medication consumption

The mean number of tablet consumption after KF surgery was 1.71 ± 1.11, and the mean number of tablet consumption after KF surgery followed by biostimulation with laser was 0.71 ± 0.76 indicating a lesser need for analgesics in the test group [Table 3].

DISCUSSION

In this study, the use of DL did not lead to any postoperative complications or impairment in the TR, indicating that this type of laser has no deleterious effects when used in combination with periodontal surgery. Furthermore, in this study, TR did not show any statistically significant difference between the two groups, and pain response on day 2 is significantly lesser in the test group than the control group. Due to the optimal dosage and treatment schedule are not constant, it is difficult to evaluate the efficiency of LLLT by direct comparison with other studies.

Despite the proposed benefit of LLLT, there are very few clinical studies using LLLT in periodontal surgery, which makes comparing the results of the current study with previous reports difficult. Randomized, controlled, clinical studies that analyzed periodontal healing response in humans using LLLT are available. The literature shows little correlation between both *in vivo* and *in vitro* animal studies and human trials when using LLLT.[14,15]

Moreover, there is only one previous study carried out by Sanz-Moliner *et al*.[11] to evaluate the postoperative pain after periodontal surgery where the author has used an 810-nm DL in conjunction with modified Widman flap surgery. In that study, the authors reported statistically significant differences which favor the test group (laser) with regard to tissue edema and PM consumption.

The pain scale used in the current study is subjective and highly dependent on the individual's pain perception. However, the same patient served as both the control and the test. The subjective measure of the pain using the scale found statistically significant differences between the control sites and the test sites on day 2 alone, and the mean number of tablet consumption was also reduced in the test group. This finding suggests that laser application may be more beneficial in procedures in which post-operative pain is expected by the patient and/or the practitioner.

CONCLUSION

To the best of our knowledge, the present study is one of the first human clinical trials that used a 980-nm DL as an adjunct to KF surgery. Although lasers currently have varied uses in dentistry, the clinical end results of *in vivo* application of low-level lasers are still unclear, and little is known regarding the optimal type, wavelength, power, energy delivered, and method of using lasers in combination with periodontal surgery. To evaluate whether lasers will provide additional benefits to periodontal therapy, additional studies in a larger number of patients are needed. Within the limitations of the current study, we conclude that the adjunct

use of a 980-nm DL with periodontal surgery (KF surgery) had a significant effect on the immediate postoperative pain and thus reducing the need for analgesic consumption.

Financial support and sponsorship
Nil.

Conflicts of interest
There are no conflicts of interest.

REFERENCES

1. Passanezi E, Damante CA, de Rezende ML, Greghi SL. Lasers in periodontal therapy. Periodontol 2000 2015;67:268-91.
2. Mester E, Spiry T, Szende B, Tota JG. Effect of laser rays on wound healing. Am J Surg 1971;122:532-5.
3. Karu T. Photobiology of low-power laser effects. Health Phys 1989;56:691-704.
4. Smith K. The photobiological basis of low-level laser radiation therapy. Laser Ther 1991;3:19-24.
5. Kana JS, Hutschenreiter G, Haina D, Waidelich W. Effect of low-power density laser radiation on healing of open skin wounds in rats. Arch Surg 1981;116:293-6.
6. Yu W, Naim JO, Lanzafame RJ. Effects of photostimulation on wound healing in diabetic mice. Lasers Surg Med 1997;20:56-63.
7. Braverman B, McCarthy RJ, Ivankovich AD, Forde DE, Overfield M, Bapna MS. Effect of helium-neon and infrared laser irradiation on wound healing in rabbits. Lasers Surg Med 1989;9:50-8.
8. Hall G, Anneroth G, Schennings T, Zetterqvist L, Rydén H. Effect of low level energy laser irradiation on wound healing. An experimental study in rats. Swed Dent J 1994;18:29-34.
9. In de Braekt MM, van Alphen FA, Kuijpers-Jagtman AM, Maltha JC. Effect of low level laser therapy on wound healing after palatal surgery in beagle dogs. Lasers Surg Med 1991;11:462-70.
10. Carrillo JS, Calatayud J, Manso FJ, Barberia E, Martinez JM, Donado M. A randomized double-blind clinical trial on the effectiveness of helium-neon laser in the prevention of pain, swelling and trismus after removal of impacted third molars. Int Dent J 1990;40:31-6.
11. Sanz-Moliner JD, Nart J, Cohen RE, Ciancio SG. The effect of an 810-nm diode laser on postoperative pain and tissue response after modified Widman flap surgery: A pilot study in humans. J Periodontol 2013;84:152-8.
12. Carranza FA, Takei HH, Cochran DL. Carranza's Clinical Periodontology. 10th ed. Noida: Saunders, Reed Elsevier India Private Limited; 2006.
13. Donnelly LR, Wyatt CC, Brondani MM. A potential gingival inflammation index for frail elders. Can J Dent Hyg 2010;44:118-23.
14. Ozcelik O, Cenk Haytac M, Kunin A, Seydaoglu G. Improved wound healing by low-level laser irradiation after gingivectomy operations: A controlled clinical pilot study. J Clin Periodontol 2008;35:250-4.
15. Khadra M, Kasem N, Haanaes HR, Ellingsen JE, Lyngstadaas SP. Enhancement of bone formation in rat calvarial bone defects using low-level laser therapy. Oral Surg Oral Med Oral Pathol Oral Radiol Endod 2004;97:693-700.