Case Report

Nonsurgical management of class III malocclusion: A case report

Pawan Kumar Bhandari, G. J. Anbuselvan

Department of Orthodontics and Dentofacial Orthopedics, KSR Institute of Dental Science and Research, Thokkavadi, Thiruchengode, Tamil Nadu, India

ABSTRACT

Not all adult Class III malocclusion patients are candidates for surgical correction. Orthodontic camouflage in patients with slight or moderate skeletal Class III malocclusions can be obtained through different treatment alternatives. This case report describes the nonsurgical treatment of a skeletal Class III malocclusion that relied on simple treatment mechanics to effectively improve the patient's profile and esthetics.

Key words: Orthodontic camouflage, skeletal Class III, crossbite, orthognathic surgery

INTRODUCTION

Class III malocclusion is a challenging orthodontic problem. A good understanding of the age, amount, and direction of growth in Class III patients comes into play when deciding between orthodontic and surgical approaches to the malocclusion.[1]

Class III malocclusion is one in which the lower first molar is mesially positioned relative to the upper first molar as described by Edward H Angle.[2] This relationship may result from a normal maxilla and a mandibular skeletal protrusion or a maxillary retrusion and a normal mandible or a combination of maxillary retrusion and mandibular protrusion.[3] Class III malocclusion patient usually have a concave facial profile, and the lower lip protrusive to the upper lip. Pseudo Class III malocclusion is caused by premature contact during the normal path of closure of the mandible and result in anterior displacement of the mandible.[4] The etiologic factors of a Class III malocclusion are the influence of genetic, environmental factors, and oral function.[5]

The treatment of choice for an adult patient with a severe skeletal Class III malocclusion and a midline deviation is combined surgical and orthodontic treatment, because of its satisfying outcome and stability.[1]

Orthodontic camouflage is a therapeutic process that most of the time, through extractions and orthodontic masks the skeletal discrepancies instead of correcting them. Therefore, dentoalveolar compensation is made without correcting the basal dysplasia.[6]

Camouflage treatment with selective extractions is usually considered only for borderline patients. However, we sometimes treat patients with severe problems who do not want surgery as a part of their treatment plans.[7]

In cases treated by orthodontic camouflage, the dental movements are often the opposite of those necessary prior to surgery, where dentoalveolar decompensation is the objective. Orthodontic camouflage treatment should be prescribed for young adults only if, before treatment begins, there are cephalometric indications that residual growth will not provoke a worsening of the deformity after treatment, causing dentofacial asymmetry. Camouflage also implies that the tooth repositioning will have a favorable effect or at least be less damaging to the facial esthetics.[8]

Address for correspondence:
Dr. Pawan D. Kumar Bhandari, Department of Orthodontics and Dentofacial Orthopedics, KSR Institute of Dental Science and Research, Thokkavadi post, Thiruchengode - 637 215, Namakkal, Tamil Nadu, India.
E-mail: pk9736@gmail.com

Access this article online	
Quick Response Code:	Website: www.jiadsr.org
	DOI: 10.4103/2229-3019.135445

Here, we report a nonsurgical treatment approach and its outcome for an adult patient with a skeletal Class III malocclusion.

CASE REPORT

Diagnosis

A female patient of age 19 came with a complaint of irregularly arranged lower front teeth and an anterior crossbite. On extraoral examination, the patient had dolicocephalic head form, leptoprosopic facial form, concave prolife, anterior divergence, and protruded lower lips [Figure 1]. On intraoral examination, the patient had an anterior crossbite in relation to all incisors, lower crowding and Class III molar and canine relationship, upper incisors are proclined, lower incisors are retroclined and forward path of closure, and reverse overjet of 2 mm and overbite of 4 mm was seen [Figure 2].

On cephalometric evaluation, patient had a skeletal Class III base with normal maxilla and prognathic mandible and vertical growth pattern [Table 1]. Maxillary incisors were proclined and mandibular incisors were retroclined. Regarding soft tissue, the lower lip was protrusive and obtuse nasolabial angle [Figure 3]. The model analysis showed that the Bolton's excess was 4.5 mm and increased tooth size arch length discrepancy of 5 mm in lower arch.

Treatment objectives:

1. Correction of anterior crossbite
2. Correction of crowding
3. To obtain ideal overjet and overbite
4. To obtain ideal esthetics.

Treatment alternatives

Stable results in skeletal Class III malocclusion with prognathic mandible can be obtained with orthognathic surgery procedure like bilateral sagittal split osteotomy (BSSO). In this case, BSSO procedure was the treatment option. Since the patient was not willing for surgery, orthodontic camouflage treatment was executed.

Under orthodontic camouflage, two treatment options were planned. First, lower first premolar extraction on both the sides. But considering the lower incisor inclination, after retraction it would be more retroclined and chances of fenestration and dehiscence on the lower anterior region. Therefore, stability would have been lost after retention. Second, one lower incisor to unravel the crowding and unilateral left first premolar extraction to correct the anterior crossbite by retraction.

Table 1. Comparison of pre- and posttreatment cephalometric values

Parameters	Pretreatment	Posttreatment
SNA angle	80	81°
SNB angle	85°	83°
ANB angle	−5°	−2°
GoGn to SN	34°	35.5°
Lower anterior face height (mm)	58 mm	61 mm
U1 to NA angle	30°	32°
U1 to NA (linear)	5.7 mm	6.5 mm
L1 to NB angle	15°	11.5°
L1 to NB (linear)	4 mm	3 mm
L1 to mandibular plane angle	94°	88°

Treatment plan

In this case, mild skeletal Class III malocclusion was camouflaged with single incisor extraction. Upper space requirement was minimal and slight proclination and arch development was sufficient in achieving good result. Lower incisor extraction was planned to maintain the straight profile and to relieve the lower anterior crowding, since there was a tooth size arch length discrepancy of more than 5 mm in the lower arch and Bolton's ratio showed mandibular excess.

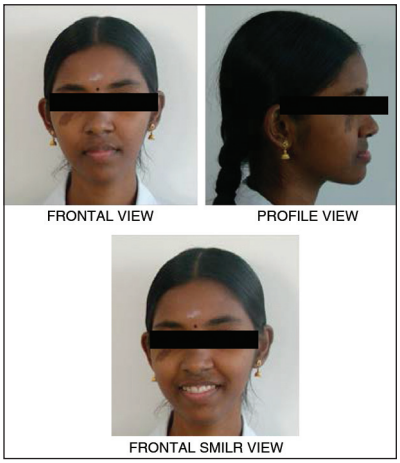

Figure 1. Pretreatment extraoral photographs

Figure 2. Pretreatment intraoral photograph

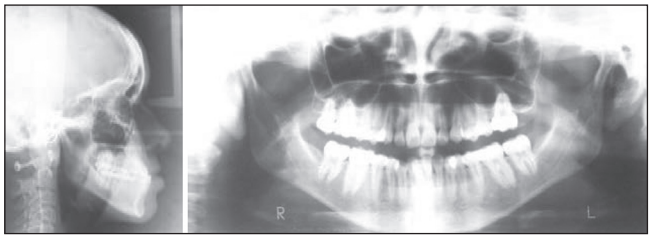

Figure 3. Pretreatment cephalograph and orthopantomogram (OPG)

On extraction of first premolar on the left side, anteriors can be retracted so that crossbite can be eliminated and also midline deviation can be corrected to obtain ideal esthetics.

Treatment progress

Treatment was started after the right lower lateral incisor and left lower first premolar extraction. 0.022" slot Roth brackets were bonded on the upper and lower arches with bilateral fixed posterior glass ionomer bite plane on the lower molar region. Leveling and alignment was started with 0.016 nickel titanium (NiTi) followed by 0.016 stainless steel (SS) and sequence of rectangular NiTi archwires in the upper and lower arches. Afer leveling and alignment, space closure was done with 0.019 × 0.025 SS having active tiebacks. Settling of occlusion was done with 0.019 × 0.025" stainless steel wire in upper and lower anterior tooth and vertical settling elastics in posterior. Retention was given with a removable Hawley's retainer in the upper arch and canine-to-canine bonded fixed retainer in the lower arch.

Treatment results

Posttreatment records showed good alignment of the upper and lower arches [Figure 4]. An esthetically acceptable smile arc was achieved after the correction of the upper anterior crossbite. There was a good occlusion between the upper and lower arches and a good intercuspation of the posterior teeth. Facial photographs and lateral cephalogram [Figure 5] showed concavity facial profile changed to straight and more esthetics than preoperatively. There was a very good improvement in the smile of the patient too [Figure 6].

DISCUSSION

The strategy for treating borderline orthodontic cases with camouflage therapy is to create dentoalveolar changes that will compensate for a skeletal base imbalance.[9] The decision as to which type of treatment is indicated is usually based on the degree of the anteroposterior and vertical skeletal discrepancy, the inclination and position of the incisors, and the dentofacial appearance.

In this case, with the skeletal and dental disharmony, the orthodontic and surgical approach would probably have been the better of the options.

Orthodontic camouflage is a viable alternative for the treatment of the mild-to-moderate skeletal discrepancies of the maxillary structures with the aim of correcting the occlusal relationships in patients who, for different reasons, decide not to be treated surgically. An ideal candidate for the camouflage treatment should present little residual growth potential, and mild-to-moderate crowding in order to be able to use the space of the extractions, thus allowing for the achievement of the orthodontic camouflage and improving the dentoskeletal relationships.

The case described here is a skeletal Class III patient with concave facial profile and crowding of the arches and anterior crossbite. The extraction of lower incisor in this case is highly favorable because it helps in maintaining the facial profile and also in the correction of lower anterior crowding. The correction of upper anterior crowding could be achieved by mild proclination of the upper anterior and passive expansion of the arch, which is an acceptable compromise in the camouflage of skeletal Class III malocclusions.

Grob[10] showed stability of skeletal Class III malocclusion by mandibular incisor extraction to maintain the facial profile. Riedel *et al.*,[11] conducted a study to compare the postretention stability of patients treated with premolar extractions and those treated with extraction of one mandibular incisor, and found more acceptable mandibular incisor alignment with single incisor extraction. Canut[12]

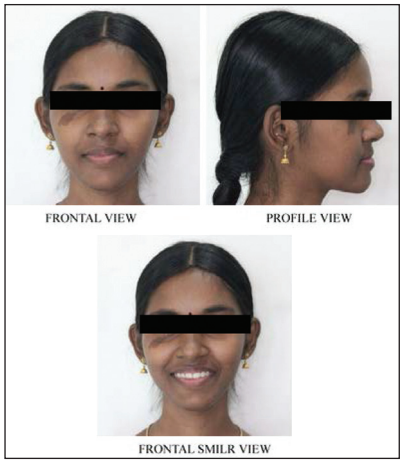

Figure 4: Post treatment extra oral photographs

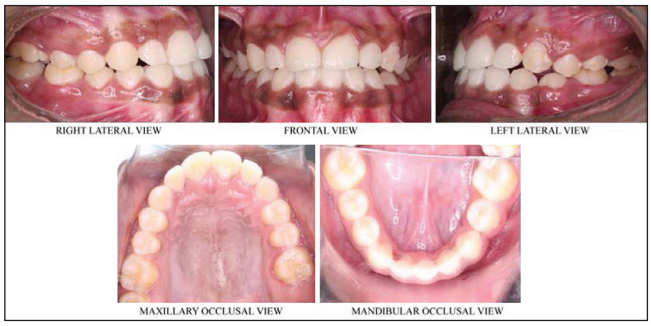

Figure 5: Posttreatment

Figure 6: Post treatment cephalogram and OPG

also found there is a better stability in patients treated with a single mandibular incisor extraction when compared with patients requiring premolar extraction.

Previous case reports have also shown good results after lower incisor extraction treatment, which is in concordance with the case presented here.

Proffit and Ackerman[13] suggested, in their concept of the "3 envelopes of discrepancies", the degree of maxillary incisor protrusion relative to mandibular incisor retrusion as a critical limitation for differentiating between orthodontic and combined orthodontic-surgical treatment. Kerr *et al*.[14] tried to establish cephalometric yardsticks to objectify treatment decisions. The most important factors that differentiated the surgery and orthodontic patients in their study were size of the anteroposterior discrepancy, inclination of the mandibular incisors, and appearance of the soft-tissue profile.

In this case, premolar extraction also favored by reducing the mandibular prognathism by reducing the concavity, obtaining an esthetic profile and coincidence of midline too.

However, skeletal Class III patients have concave profiles, with thin basal bone over the symphysis.[15]

Significant lingual inclination or distal movement of the incisors after mandibular premolar extractions can negatively affect the concave profile compared with nonextraction[16] and can even induce unwanted complications such as root exposure and resorption of the incisors.[17,18] Even after treatment, difficulties in plaque control of the lingual surface can lead to plaque accumulation and periodontal diseases.

The retraction of the mandibular incisors occurred without significant loss of anchorage in the posterior segment, and in spite of the extraction of first left lower premolar, because of the intermaxillary Class III elastics. Class III elastics also contribute to correction of the overbite and overjet, which was at the cost of retrusion of the mandibular incisors and permitted by extraction of lower premolar.

CONCLUSION

Treatment of a Class III patient with extraction of mandibular first premolar and lower incisor was reported. The basis for this treatment approach was presented, and the final treatment result was obtained. The proposed treatment objectives were to obtain a stable dental articulation and good esthetics instead of the skeletal disharmony and dental Class III malocclusion was achieved.

REFERENCES

1. Baccetti T, Reyes BC, McNamara JA Jr. Craniofacial changes in Class III malocclusion as related to skeletal and dental maturation. *Am J Orthod Dentofacial Orthop* 2007;132:171.e1-171.e12.
2. Proffit WR, Fields HW Jr. Contemporary orthodontics. 3rd ed. *St Louis: Mosby*; 2000 [Textbooks].
3. William S, Andersen CE. The morphology of the skeletal potential Class III skeletal pattern in the growing child. *Am J Orthod* 1986;89:302-11.
4. Rabie AB, Gu Y. Diagnostic criteria for pseudo class III malocclusion. *Am J Orthod Dentofacial Orthop* 2000;117:1-9.
5. Moreno Uribe LM, Vela KC, Kummet C, Dawson DV, Southard TE. Phenotypic diversity in white adults with mild/severe Class III malocclusal. *Am J Orthod Dentofacial Orthop* 2013;144:32-42.
6. Costa Pinho TM, Ustrell Torrent JM, Correia Pinto JG. Orthodontic camouflage in the case of the skeletal Class III malocclusion. World *J Orthod* 2004;5:213-23.
7. Lin J, Gu Y. Preliminary investigation of nonsurgical treatment of severe skeletal Class III malocclusion in the permanent dentition. *Angle Orthod* 2003;73:401-10.
8. Hisano M, Chung CR, Soma K. Nonsurgical correction of skeletal class III malocclusion with lateral shift in an adult. *Am J Orthod Dentofacial Orthop* 2007;131:797-804.
9. Graber TM, Vanarsdall RL. Orthodontics: Current principles and techniques. 3th ed. St. *Louis Mosby*; 2000 [Textbooks].
10. Grob DJ. Extraction of a mandibular incisor in a class I malocclusion. *Am J Orthod Dentofacial Orthop* 1995;108:533-41.
11. Riedel RA, Little RM, Bui TD. Mandibular incisor extraction: Post-retention evaluation of stability and relapse. *Angle Orthod* 1992;62:103-16.
12. Canut JA. Mandibular incisor extraction: Indications and long-term evaluation. *Eur J Orthod* 1996;18:485-9.
13. Proffit WR, Ackerman JL. A systematic approach to orthodontic diagnosis\ and treatment planning. In: Graber TM, Swain BF, editors. Current Orthodontic Concepts and Techniques. 3rd ed. *St Louis: C.V. Mosby* 1985 [Textbooks].
14. Kerr WJ, Miller S, Dawber JE. Class III malocclusion: Surgery or orthodontics? *Br J Orthod* 1992;19:21-4.
15. Yang WS. Morphology of mandibular symphysis and positioning of lower incisors in the skeletal Class III malocclusion. *Korean J Orthod* 1985;15:149-53.
16. Battagel JM, Orton HS. Class III malocclusion: A comparison of extraction and non-extraction techniques. *Eur J Orthod* 1991;13:212-22.
17. McFadden WM, Engstrom C, Engstrom H, Anholm JM. A study of the relationship between incisor intrusion and root shortening. *Am J Orthod Dentofacial Orthop* 1989;96:390-6.
18. Kaley J, Phillips C. Factors related to root resorption in edgewise practice. *Angle Orthod* 1991;61:125-32.

How to cite this article: Bhandari PK, Anbuselvan GJ. Nonsurgical management of class III malocclusion: A case report. J Indian Acad Dent Spec Res 2014;1:35-8.

Source of Support: Nil, **Conflict of Interest:** None declared